

# Overcoming Recalcitrant Acne: A Case on the Combined Use of Arctium Lappa (Burdock) Orally with Electromagnetic Route

<sup>1</sup>Dr. Avani B. Patel, <sup>2</sup>Dr. Vipul R. Shastri

<sup>1</sup>Associate Professor, Department of Anatomy, Vidhyadeep Homoeopathic Medical college and research centre, Anita, Kim, Vidhyadeep University, Surat, India

<sup>2</sup>I/C Provost /Principal/Professor and HoD, Department of Pathology and Microbiology, Vidhyadeep Homoeopathic Medical college and research centre, Anita, Kim, Vidhyadeep University, Surat, India

**Abstract:** Acne vulgaris is a common skin condition among young individuals, with papules, pustules, and comedones appearing on the face most frequently, followed by the back and chest. The hair follicles are blocked by these factors, eventually leading to inflammation and acne. Bacterial populations and hormone fluctuations also contribute to the condition. The present study investigates the efficacy of oral and electromagnetic route administration of Arctium lappa (burdock) in managing papulopustular acne. Arctium lappa is known for its anti-inflammatory and antimicrobial properties, traditionally used in dermatology. Additionally, the electromagnetic pathway was suggested as a potential therapeutic intervention to reduce inflammation and bacteria in acne lesions. However, few studies have examined the combination of these strategies.

A lengthy case series was conducted on a 35-year-old woman with papulopustular acneiform eruptions on her cheeks and forehead. The treatment included oral administrations of Arctium lappa 200 combined with the electromagnetic route. After 12 weeks, the patient demonstrated significant improvement (Global Acne Grading System: 23 to 0), followed by a reduction in the number and severity of acne lesions. Combining Arctium lappa with the electromagnetic route might offer a new and promising approach for treating resistant acne, providing an option for patients who have not responded to conventional therapies. Further studies are required to explore the mechanism and optimize the protocol for broader clinical application.

**Keywords:** Acne vulgaris, Arctium lappa, burdock, Homoeopathy, Electromagnetic route treatment, dermatology, case.

## Introduction:

Acne vulgaris is a chronic dermatologic disease of the pilosebaceous unit, and its pathogenesis involves sebum overproduction, increased ductal hypercornification, bacterial

colonization (mainly *Propionibacterium acnes*), and inflammation<sup>10</sup>. The prevalence is higher around adolescence, and the incidence is 0.74%, with an average age of 30.1 years<sup>4</sup>. Even more concerning is the saddening fact erupting as shown in cost distribution over both sexes, with fair surety pointing to females diligently affording the rampant majority of the different types such as persistent and inflammatory acne type mainly saturating the cheeks, thereby carrying any danger accompanied with facial scarring.

The main treatment for acne consists of multiple conventional allopathic drugs like topicals, complementary and alternative medicines, physical treatments, and combination therapies. However, even these treatments offer little help and are accompanied by issues like local inflammation due to acid treatment, redness on the skin due to radiofrequency or ultraviolet radiation to induce elastin formation or make collagen fragments formed by the breakdown of collagen leading to scarring and pigmentation<sup>11</sup>. Plus, antibiotic resistance and the medical need are paving the path for the exploration of alternative therapies<sup>16</sup>

Homeopathic interventions thereby personalize acne management by creating individualized treatment plans based on a patient's symptoms, constitution, and health<sup>6</sup>. Homeopathy seeks to achieve this through the use of heavily diluted remedies which contribute to minimizing side effects and thus, obtaining long-lasting relief by treating the underlying causes as well as the physical symptoms of the disease<sup>8</sup>. This holistic method here, not only focuses on the skin but also considers the emotional and mental aspects of the person, thereby, giving more importance to the whole healing process.

Along with the medicinal aspects, non-medicinal therapeutic means are also talked by Hahnemann<sup>9</sup> which promote a whole range of techniques like magnetism, electricity, and galvanism<sup>13</sup>. The new therapies possess the potential of supplementing the traditional methods or a branched-out direction by themselves.

Magnet therapy as an example strongly guarantees blood ionization<sup>3</sup>, which in turn allows for a smooth flow that relieves pain and inflammation. In the same manner, galvanic applications exploit chemical effects to get beauty benefits, among them electrolysis and iontophoresis<sup>19</sup>, which are of historical origin in the late 19th century.

We are going to tackle this subject by inquiring into the issue of acne treatment. Traditional and alternative methods are included, as well as non-medicinal therapeutic measures that can complement or enhance treatment outcomes. We are giving all these details in the hope of getting acne care done holistically by seizing the opportunity to tackle both the physical and emotional well-being of the affected person.

### **Literature review:**

S. Kashyap (2022)<sup>15</sup>: Focused on East India, Kashyap's study identified multiple risk factors for adult-onset acne, shedding light on the complex interplay of genetic predisposition, environmental factors, and lifestyle habits. The emphasis on hydration as a skin health promoter adds a practical dimension to acne management strategies.

Pathrikar Anupama (2022)<sup>12</sup>: This study delved into the clinical presentation of acne vulgaris and the efficacy of homeopathic treatments. By examining commonly prescribed remedies and symptomatology, it provided clinicians with valuable insights into individualized therapeutic approaches, particularly in cases of severe or refractory acne.

Pramanil A. (2022)<sup>14</sup>: Pramanil's article juxtaposed homeopathic and conventional approaches to acne treatment, highlighting the holistic paradigm of homeopathy in addressing underlying imbalances. This comprehensive perspective underscores the importance of individualized care in acne management.

Sharma et al. (2020)<sup>16</sup>: The efficacy of homeopathy in acne treatment was investigated in this study, showcasing notable improvements in disease severity and quality of life. By identifying specific remedies and their corresponding clinical outcomes, it advocates for the integration of complementary approaches in dermatological practice.

Zhong H et al. (2021)<sup>18</sup>: Innovative non-drug therapies, such as ultrasound-assisted aloe vera gel application, offer promising outcomes in acne management, leveraging the synergistic benefits of natural compounds and advanced delivery systems. Its safety profile and efficacy position it as a viable adjunct or alternative to conventional treatments.

Gregor Dürrenberger et al. (2018)<sup>7</sup>: The review on electromagnetic fields (EMF) in cosmetics elucidated the therapeutic potential of DC power, offering insights into its mechanisms of action and safety considerations. While further research is warranted, EMF-based modalities represent a novel frontier in acne therapeutics.

Anjali Miglani (2013)<sup>2</sup>: Miglani's study explored the therapeutic potential of *Articum Lappa* in acne management, demonstrating promising results in improving acne severity and quality of life. Despite limitations, such as sample size constraints, it highlighted the relevance of botanical interventions in dermatological care.

### **Case study**

Case No. of Research:

#### **Patient Information:**

- Name: ABC

- Age: 35 years

- Gender: Female

- Occupation: SMC Inspector

- Date: 12/12/2023

#### **Chief Complaint:**

- Mild to severe papulopustular acne since 6 months.

**Presenting Complaints:**

- Patient is having papulopustular acne on both cheeks and Forehead , with redness and occasional itching, especially after perspiration and exposure to heat since 6 months.
- Amelioration after ice application or cold water application.

**Medical History:**

- Past Medical History: LSCS in the past (Before 7 Years), and the female child passed away at 1 year of age. Now having 2<sup>nd</sup> Baby girl Child of 1.2 Years whois healthy.
- Family Medical History: Father passed away 15 years ago due to heart failure.
- Medications: Previously taken allopathic and topical treatments for acne, but the condition recurred after stopping the medication.

**Personal History:**

- Diet and Lifestyle: Regular
- Skincare Routine: Washes face twice a day and applies sunscreen for the past 8 months.
- Emotional Well-being: Good

**Constitutional Analysis:**

- General Constitution: Tall and overweight
- Temperament: Extroverted
- Susceptibility: Allergy to dust
- Modalities: Aggravation after applying makeup

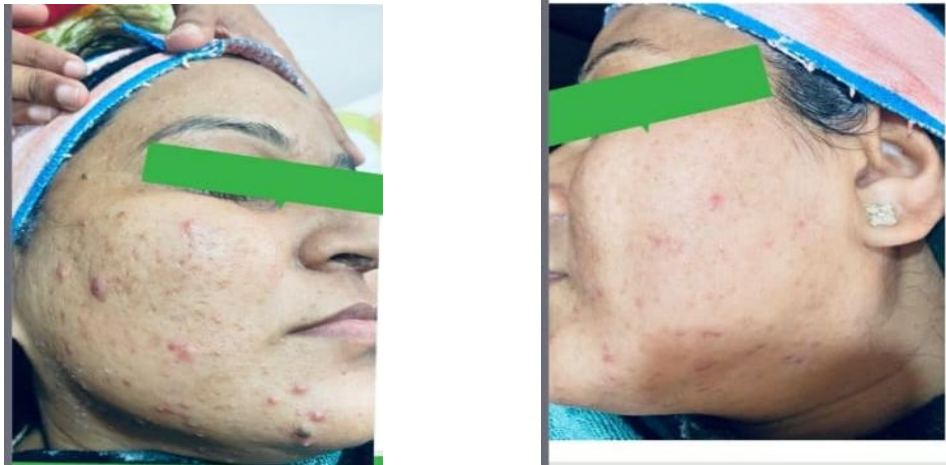**Case Evaluation:**

- Analysis of Symptoms: The patient has papulopustular acne lesions on both cheeks, with redness and occasional itching. The condition is aggravated after perspiration, exposure to heat, and application of makeup, and ameliorated by ice or cold water application.

**Treatment Plan:**

- Selected Remedy: Arctium lappa
- Potency: 200
- Administration: Oral + Electromagnetic Route

**Outcome and Follow-up:-** Progress: Three photos have been provided showing the patient's condition on the day of treatment (12/12/2023). According to the Global Acne Grading System (GAGS)<sup>1,5,17</sup>, the baseline score was 23, indicating moderate acne severity.



(A)

(B)

Image 1.1 Acne Progression and Severity on 12/12/2023

- Follow-up: Scheduled follow-up appointments every 2 weeks to monitor progress:

26/12/2023 - Newly appeared acne on both cheeks

- This indicates a worsening of acne, so the score may remain the same or increase slightly.

Location	Factor (F)	Severity (S)	Local Score (F×S)
Forehead	2	4 (Papules) 1 (Pustule)	10
Right Cheek	2	2 (Papules)	4
Left Cheek	2	6 (Papules)	12
Nose	1	0	0
Chin	1	1 (Papules)	1
Chest and Upper back	3	0	0
<b>Total Score</b>			<b>27</b>

Table 1.1 Acne Progression and Severity on 26/12/2023

09/01/2024 - Itching and redness slightly decreased (Both cheeks and forehead)

- Assuming a slight improvement, the scoring could be:



Location	Factor (F)	Severity (S)	Local Score (FxS)
Forehead	2	2 (Papulopustular)	4
Right Cheek	2	4 (Papulopustular)	8
Left Cheek	2	4 (Papulopustular)	8
Nose	1	1 (Comedones)	1
Chin	1	0 (Nil)	0
Chest and Upper back	3	0 (Nil)	0
<b>Total Score</b>			<b>19</b>

Table 1.2 Acne Progression and Severity on 09/01/2024

Total Score: 19 (Moderate)

23/01/2024 - On 6th week, severity is decreased (Both cheeks and forehead)

- Assuming further improvement, the scoring could be:

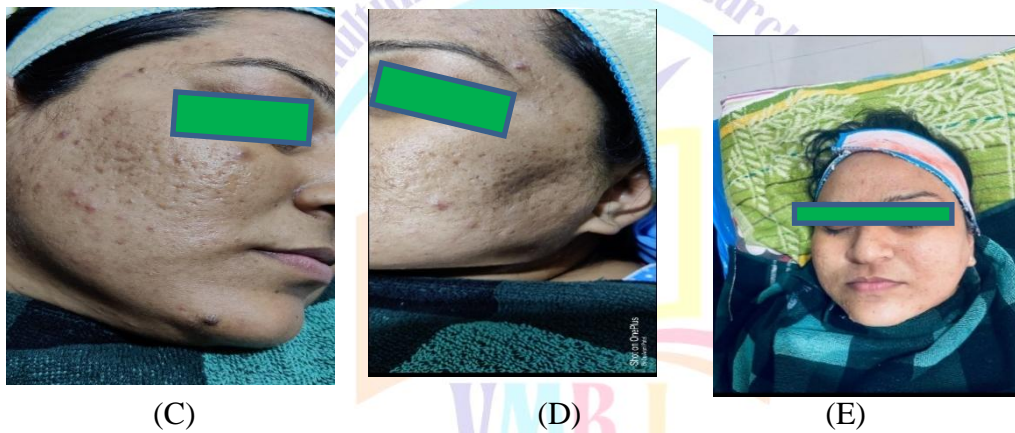


Image 1.2 Acne Progression and Severity on 23/01/2024

Location	Factor (F)	Severity (S)	Local Score (FxS)
Forehead	2	2 (Comedones)	2
Right Cheek	2	2 (Comedones)	4
Left Cheek	2	2 (Comedones)	4
Nose	1	0 (Nil)	0
Chin	1	0 (Nil)	0

Chest and Upper back	3	0 (Nil)	0
<b>Total Score</b>			<b>10</b>

Table 1.3 Acne Progression and Severity on 23/01/2024

Total Score: 10 (Mild)

06/02/2024 - Number of acne decreased (Both cheeks and forehead)

Location	Factor (F)	Severity (S)	Local Score (FxS)
Forehead	2	1 (Comedones)	2
Right Cheek	2	2 (Comedones)	4
Left Cheek	2	1	2
Nose	1	0 (Nil)	0
Chin	1	0 (Nil)	0
Chest and Upper back	3	0 (Nil)	0
<b>Total Score</b>			<b>8</b>

Table 1.4 Acne Progression and Severity on 06/02/2024

Total Score: 8 (Mild)

20/02/2024 - Number of acne decreased (Both cheeks and forehead)

Location	Factor (F)	Severity (S)	Local Score (FxS)
Forehead	2	0 (Nil)	0
Right Cheek	2	2	4
Left Cheek	2	1	2
Nose	1	1	0
Chin	1	0 (Nil)	0
Chest and Upper back	3	0 (Nil)	0
<b>Total Score</b>			<b>6</b>

Table 1.5 Acne Progression and Severity on 20/02/2024

Total Score: 6 (Mild)

05/03/2024 - 12th week (patient reported no acne on both cheeks and forehead)

Location	Factor (F)	Severity (S)	Local Score (FxS)
Forehead	2	0 (Nil)	0
Right Cheek	2	0 (Nil)	0
Left Cheek	2	0 (Nil)	0
Nose	1	0 (Nil)	0
Chin	1	0 (Nil)	0
Chest and Upper back	3	0 (Nil)	0
<b>Total Score</b>			<b>0</b>

Table 1.6 Acne Progression and Severity on 05/03/2024

Total Score: 0 (Clear)

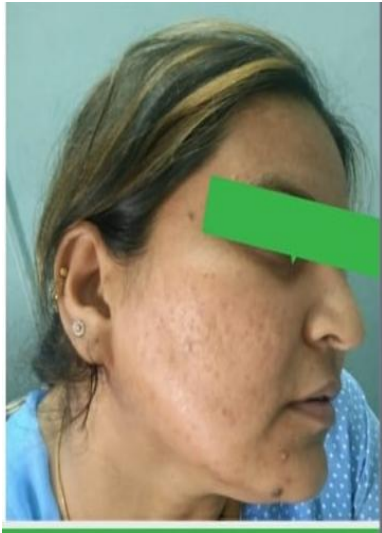- This scoring demonstrates the gradual improvement in the patient's acne condition over the 12-week treatment period, with the final score of 0 indicating a complete clearance of acne lesions in the evaluated areas.
- Photographs recording: High-resolution photographs taken before, during, and after treatment for objective evaluation and documentation.

**So on this Follow ups**

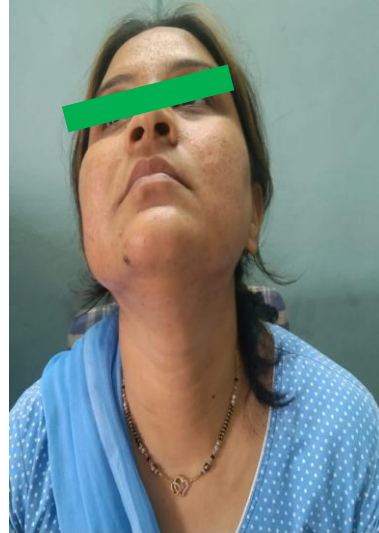Date	Observation	GAGS Score	Severity
12/12/2023	On 1 <sup>st</sup> day of treatment	23	Moderate to severe
26/12/2023	Newly appeared acne on both cheeks	27	Worsening
09/01/2024	Itching and redness slightly decreased	19	Moderate
23/01/2024	Severity decreased (6th week)	10	Mild
06/02/2024	Number of acne decreased	8	Mild
20/02/2024	Number of acne decreased	6	Mild
05/03/2024	No acne reported (12th week)	0	Clear

Table 1.7 Acne Progression and Severity Over Time

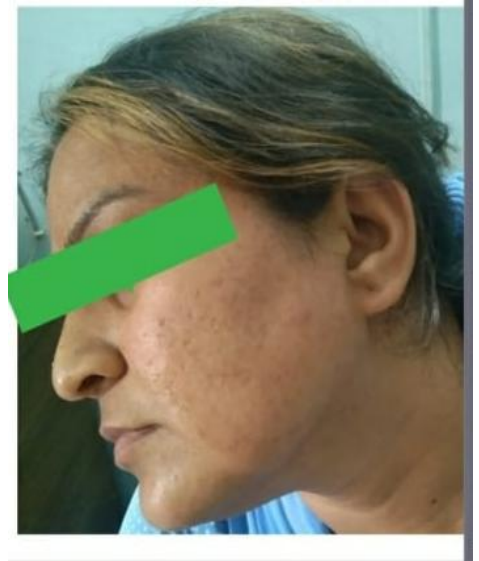



(F)



(G)



(H)

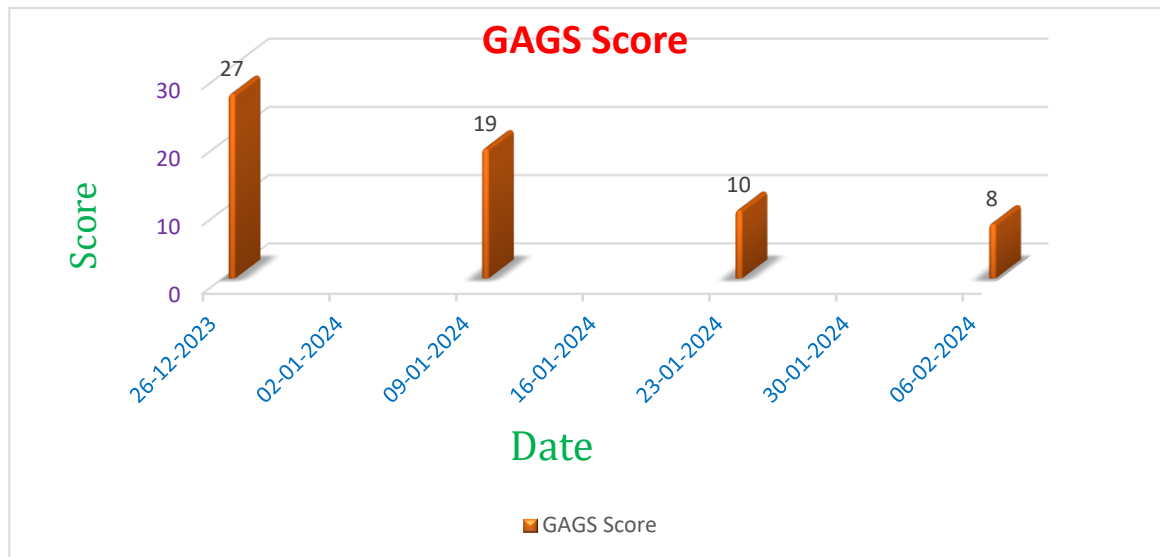


Image 1.3 Acne Progression and Severity on 05/03/2024

Table 1.8 Graphical Presentation of Acne Progression and Severity Over Time

### Outcome Measures:

- Primary Outcome: Significant improvement in the Global Acne Grading System score, from 23 (Moderate) at baseline to 0 (Clear) at the 12th week.
- Secondary Outcome: Marked reduction in the number of papules, pustules, and overall severity of acne lesions, as evidenced by the decreasing GAGS scores over time.

Photographs recording: High-resolution photographs taken before, during, and after treatment have been provided for objective evaluation and documentation of the treatment progress.

## Analysis

The dataset provides a comprehensive timeline of a patient's acne progression and response to treatment over a 12-week period from December 2023 to March 2024. The treatment involved the administration of Articum lapa 200 both orally and through an electromagnetic route. This dual-mode administration was intended to enhance therapeutic outcomes by combining traditional oral medication with innovative electromagnetic delivery.

## Initial Condition

On December 26, 2023, the patient presented with newly appeared acne on both cheeks, characterized by a GAGS (Global Acne Grading System) score of 23. This score, falling within the severe category, indicated a high burden of acne lesions, inflammation, and potential discomfort for the patient. This initial high severity score set a challenging baseline for assessing the efficacy of the treatment regimen.

## Findings and Response to Treatment

- **December 26, 2023:** After the treatment, in 1<sup>st</sup> followup the acen is increased. All the complaints re as it is
- **January 9, 2024:** By the second observation, there was a noticeable decrease in itching and redness, with a GAGS score reduction to 19, indicating a moderate severity level. This early response suggests the treatment began to have a beneficial effect on inflammatory symptoms.
- **January 23, 2024:** At the six-week mark, there was a significant reduction in the severity of the acne, with the GAGS score dropping to 10. This score signifies a mild severity, showing that the treatment had continued to be effective, reducing both the number and severity of acne lesions.
  - **February 6, 2024:** Further improvement was observed with a GAGS score of 8, still within the mild severity range. This suggests a consistent positive response to the ongoing treatment regimen.
- **February 20, 2024:** The GAGS score decreased further to 6, demonstrating a continued reduction in acne lesions and severity.
- **March 5, 2024:** By the twelfth week, the patient reported no acne, achieving a GAGS score of 0, which indicates a clear skin condition.

## Results

The overall trend from severe to clear acne over the 12-week period demonstrates a consistent and progressive improvement in the patient's condition. The dual administration of Articum lapa 200, both orally and via the electromagnetic route, appears to have been

particularly effective. The steady decline in GAGS scores underscores the potential benefits of this combined treatment approach.

### **Recommendations**

The combination of oral and electromagnetic administration of Articum lapa 200 might have contributed to the enhanced therapeutic outcomes observed. Oral administration ensures systemic absorption of the medication, targeting acne from within, while the electromagnetic route may enhance localized delivery and absorption of the medication at the skin level, potentially increasing its efficacy.

### **Summary**

The data indicates that Articum lapa 200, when administered both orally and through an electromagnetic route, effectively reduced the severity of acne over a 12-week period. The patient's GAGS scores decreased consistently from a severe level of 23 to a clear level of 0, indicating a high level of treatment efficacy. This suggests that the dual administration method could be a potent strategy for managing acne. Future research should explore the comparative effectiveness of this dual approach against single administration methods to further validate these findings and optimize treatment protocols.

### **References:**

1. Adityan, Balaji & Kumari, Rashmi & Thappa, DM. (2009). Scoring systems in acne vulgaris. Indian journal of dermatology, venereology and leprology. 75. 323-6. 10.4103/0378-6323.51258.
2. Anjali Miglani, Raj K. Manchanda, Observational study of Arctium lappa in the treatment of acne vulgaris, Homeopathy, Volume 103, Issue 3, 2014, Pages 203-207, ISSN 1475-4916, <https://doi.org/10.1016/j.homp.2013.12.002>
3. Bansal, Dr. H.L., Dr. R.S. Bansal, Magnetic cure for common disease, 1984, published by paperbacks, Delhi
4. Budamakuntla L, Parasramani S, Dhoot D, Deshmukh G, Barkate H. Acne, in Indian population: An epidemiological study evaluating multiple factors. IP Indian J Clin Exp Dermatol 2020;6(3):237-242.
5. Doshi A, Zaheer A, Stiller MJ. A comparison of current acne grading systems and proposal of a novel system. Int J Dermatol. 1997 Jun;36(6):416-8. doi: 10.1046/j.1365-4362.1997.00099.x. PMID: 9248884.
6. D'Souza Francisco, Dr. Leela, MD (Hom), MSc (Hom) HMD in partial fulfillment of the degree of HMD obtained in 1998 from The British Institute of Homeopathy, UK. [www.homeopathy2health.com](http://www.homeopathy2health.com)

7. Gillies.Malcolrue ,M,cDavid,IheHomoeopathic treatment of Acne,Department of Homoeopathy,Technikon Natal,February 1994
8. Gregor Dürrenberger et All ,EMF Applications in Cosmetics and Wellness, 2018 EMF-Med 1st World Conference on Biomedical Applications of Electromagnetic Fields (EMF-Med)2018
9. Hahnemann's organon of medicine by B.K. sarkar forwarded by J.N. majumdar 10th reprint edition 2006-2007 published by Birla publication pvt. Ltd, shahdara delhi-110032.
10. Kalas wolff,Lowell A. Goldsmith,Stephen I.Katz,Barbara,Amy,David,Fitzpatrick's in general medicine,7thedition, vol-1 and 2,McGraw Hill Companies publication,pg No.728

