

Eczema treated with LM potency of individualized homeopathic medicine: A case report

Piyush S. Gujarathi^{1,2*}, Pranjal P. Gujarathi³

¹Vidhyadeep Homeopathic Medical college and research Centre, Vidhyadeep University,
Anita, Surat

²Dr. Gujarathi's Homeopathic Clinic, Kim, Surat

³Vidhyadeep Institute of Pharmacy, Vidhyadeep University, Anita, Surat

ABSTRACT:

Eczema is a chronic, recurrently appearing skin condition possessing characteristic symptoms of reddishness, itching, dry skin, scaly patches, oozing or crusting, and blisters caused by diminished barrier function. Emollients and corticosteroids are the available treatment regimens in conventional medicine but all these medicaments suppress the skin aliment and the recurrence of disease to a greater extent occurs after stopping treatment. Homeopathic systems of medicine contributed equally to the therapeutic cure of eczema without recurrence of aliment. The report contains a case of 42 a male with the development of eczema on the thumbs of hands for long. The patient was treated with graphitis 0/1. The effectiveness of homeopathic remedies in eczema is shown in this case report. It provides the basis for conducting large-scale studies with different study designs in the treatment of eczema with homeopathic medicines.

Keywords: Homeopathy, Eczema, Atopic dermatitis, Graphitise, Totality of symptoms

INTRODUCTION

Eczema is a chronic, recurrent inflammatory dermatological disease characterized by redness, itching, dry skin, scaly patches, oozing or crusting, and blisters caused by diminished barrier function. The primary characteristic of eczema is itching(Das & Sethi, 2021; Sohn et al., 2011). Eczema is frequently termed dermatitis, but dermatitis is commonly referred to atopic dermatitis(Kaur et al., 2023; Parveen, 2016). The primary characteristic of eczema is itching. It affects more commonly in older population and reduces the Quality of life of the patient. Eczema is diagnosed clinically based on subjective and objective symptoms(Mandal et al., 2021; Meena et al., 2020). The disease can be manageable to some extent by avoiding contact with irritants and continuous use of emollients.

According to homeopathic principles, skin conditions reflect underlying systemic diseases. Therefore, it is best to take a constitutional approach to treatment that seeks to identify the root cause of the skin condition rather than solely relying on suppressive local treatments(Bagdi & Ram, 2020). Suppressing skin conditions in this way may risk more

serious systemic health issues developing over time. While the body of literature on homeopathic treatments for eczema is substantial, well-controlled research studies remain limited. This case report details the successful management of a patient's eczema using an individually selected homeopathic medicine, adding to the accumulating evidence that a homeopathic approach can effectively address such dermatological conditions(Kaur et al., 2023; Meena et al., 2020). By tailoring the remedy to the individual's unique symptom picture, this case demonstrates homeopathy's potential to resolve eczema where conventional options have failed or provided only temporary relief. Further research in this area could help more patients benefit from homeopathy's gentle and holistic approach to relieving their skin complaints(Kaur et al., 2023; Mahesh et al., 2021; Meena et al., 2020).

This study presents the successful therapeutic cure of eczema using the homeopathic remedies graphites. The medicine was selected after a thorough therapeutic assessment of the patient's symptoms.

Case report

A 42-year-old male patient visited the Clinic on 15 June 2022 with the development of eczematous lesions over the thumbs of both hands. The patient developed these lesions 6 to 7 months prior. During his first visit, the patient has itching with sticky watery discharge from the lesion. Lesion initially developed on the right-hand thumb followed by the left-hand thumb. Along with chief complaints patient suffering from constipation for 6 months. He is a milk vendor and has no history of chemical contact and using allopathic ointments.

Graphites 0/1 were selected based on complaints of sticky watery discharge from skin lesions and associated complaints of constipation.

The patient was instructed not to use any other treatment for the same condition and to moisturize with coconut oil in case of dryness.

Follow-Ups:

A patient was revisited on 19th July 2023, and the itching and pain in affected areas decreased also there was no discharge from the eczematous areas. The patient also got relaxation from constipation. Graphites 0/1 was twice a day and repeated for 15 days.

The patient revisited the clinic on 5th August 2023 eruption was decreased without any itching in between the follow-ups. The constipation was completely relieved. The frequency of stool became daily with soft stool. The graphites 0/1 once a day and Sac. Lac. 4 pills thrice a day were prescribed for 15 days.

The patient returned on 23rd August 2023 with relief in all the symptoms and hence Sac. Lacc. was given.

The patient was followed by up to 15 January 2024 and the placebo was continuously administered as the patient improved steadily. At the last follow-up, the patient had clear and healthy skin and was feeling better with symptoms of constipation also.

• **DISCUSSION AND CONCLUSION**

Various studies exhibited that homeopathic interventions are highly effective in treating skin conditions. According to homeopathy, external diseases are occurred because of underlying internal derangements and they should be treated internally not by local application of medicine. This case report indicates the effectiveness of the homeopathic medicine in eczema. Based on the patient's presenting symptoms and after referring materia medica Graphitise was selected. Graphitis was administered in 0/1 potency. and a marked improvement was observed in 15th-day follow-ups. The discharge from the eruption was stopped, and itching and paining were reduced as well as the constipation was also alleviated. The eruption diminished gradually in the next follow-up. After one month of treatment, the eruptions completely disappeared, the consistency of the stool became soft with daily passage and the patient felt relaxed. Not only his physical symptoms but his anxious behavior was controlled as well as decision-making power was improved. He was kept on a placebo. To check the further recurrence no further disease recurrence was noticed, patient was overall good without any complaints.

According to this case report it observed that the homeopathic medicine prescribed on the totality of symptoms of eczema had shown beneficial results. However, this is only one case report, and further larger studies with specific study designs and large sample sizes are warranted to determine the effectiveness of homeopathic treatment in eczema.

Prescription – date – 4/7/2023 – Graphites 0/1 BD for 15 days

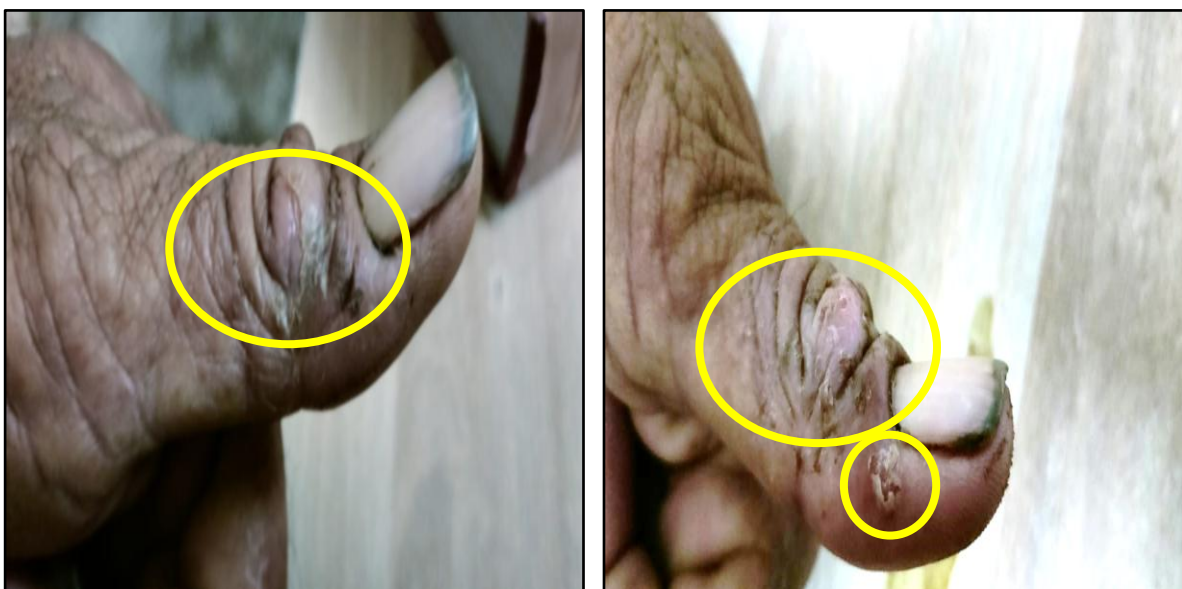

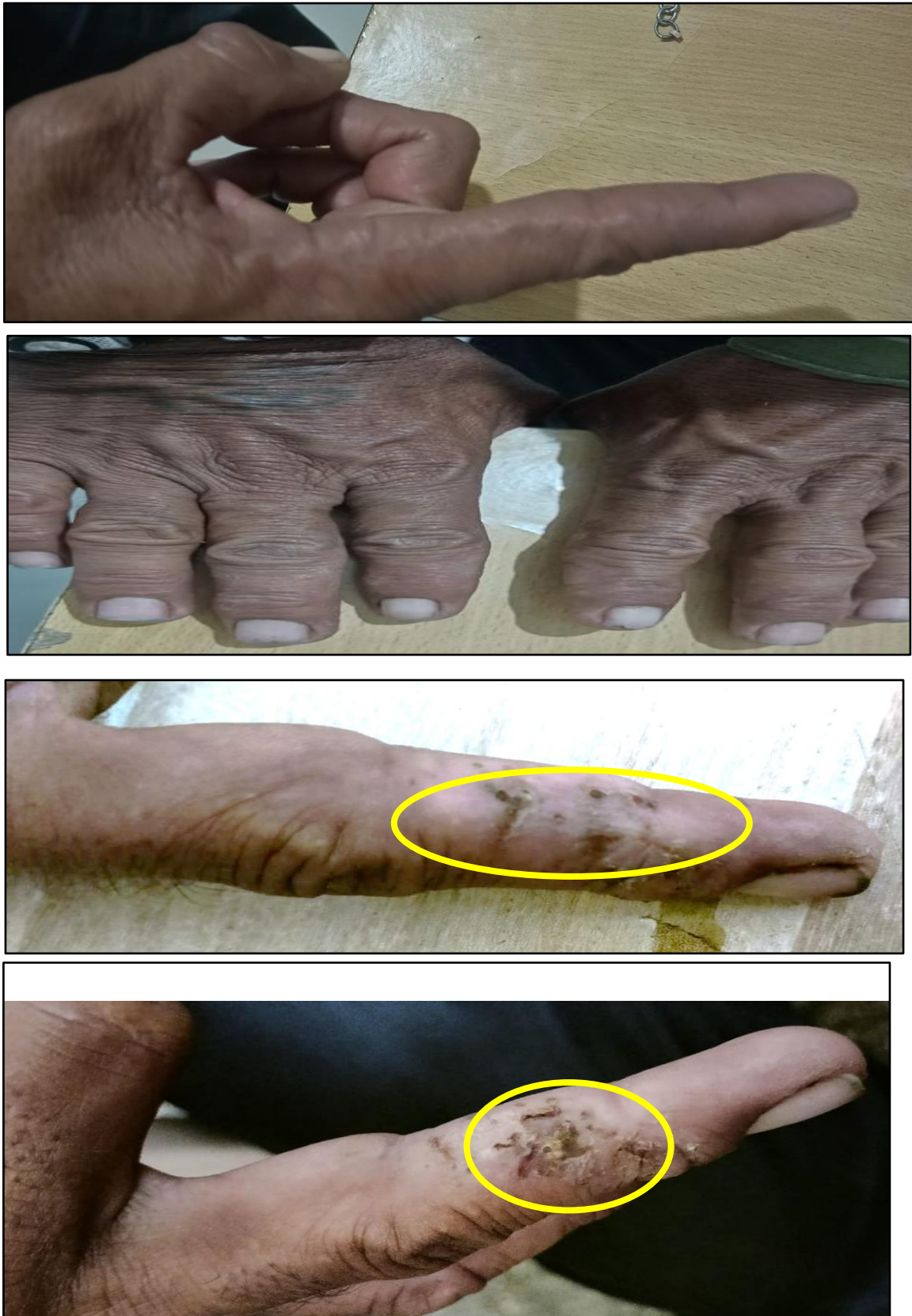


Figure 1 Before treatment

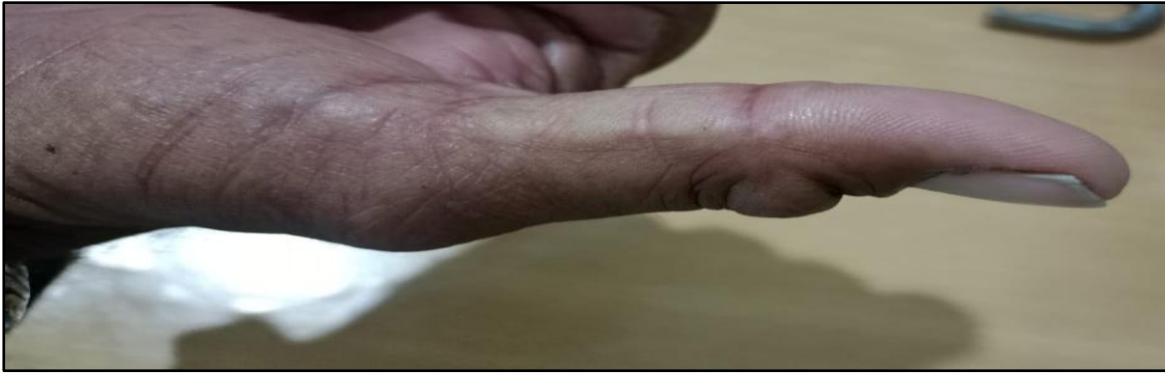

Figure 2 After 15 days of treatment

- **DECLARATION OF PATIENT CONSENT**

The author certifies that they have obtained all appropriate patient consent.

- **FINANCIAL SUPPORT AND SPONSORSHIP**

Nil

- **CONFLICT OF INTEREST**

There is no conflict of interest.

- **REFERENCES:**

- Bagdi, Dr. N. & Ram, Dr. H. (2020). A case report for successful treatment of atopic dermatitis (AD) with a Constitutional homeopathic medicine Natrum muriaticum. *International Journal of Homeopathic Sciences*, 4(2), 46–51.
<https://doi.org/10.33545/26164485.2020.v4.i2a.150>
- Das, A. & Sethi, S. (2021). *Concise Dermatology* (R. Sarkar, Ed.). CRC Press.
<https://doi.org/10.1201/9781003081609>
- Kaur, H., Parveen, G., Subhra Sengupta, S., Hashmi, T. & Resident, J. (2023). *Homeopathic Management of Eczema: A Case Report*. <https://doi.org/10.5281/zenodo.10446391>
- Mahesh, S., Mallappa, M., Habchi, O., Konstanta, V., Chise, C., Sykiotou, P. & Vithoulkas, G. (2021). Appearance of Acute Inflammatory State Indicates Improvement in Atopic Dermatitis Cases Under Classical Homeopathic Treatment: A Case Series. *Clinical Medicine Insights: Case Reports*, 14, 117954762199410. <https://doi.org/10.1177/1179547621994103>
- Mandal, S., Biswas, B. & Abbas, J. (2021). Atopic dermatitis in a 2-year-old child treated with individualised homeopathic medicine: A case report. *Journal of Integrated Standardized Homeopathy*, 4, 86–93. https://doi.org/10.25259/jish_13_2021
- Meena, B. S., Kumar, A. & Bagdi, N. (2020). A case of eczema treated with homeopathic medicine. *Journal of Integrated Standardized Homeopathy*, 3, 20–23.
https://doi.org/10.25259/jish_1_2020

- Parveen, S. (2016). Homoeopathic treatment in a case of co-morbid atopic dermatitis and depressive disorder. *Indian Journal of Research in Homoeopathy*, 10(1), 75.
<https://doi.org/10.4103/0974-7168.179145>
- Sohn, A., Frankel, A., Patel, R. V. & Goldenberg, G. (2011). Eczema. *Mount Sinai Journal of Medicine: A Journal of Translational and Personalized Medicine*, 78(5), 730–739.
<https://doi.org/10.1002/msj.20289>

