

## ECZEMA TREATED WITH LM POTENCY OF INDIVIDUALIZED HOMEOPATHIC MEDICINE: A CASE REPORT

Piyush S. Gujarathi<sup>1,2\*</sup>, Pranjal P. Gujarathi<sup>3</sup>

<sup>1</sup>Vidhyadeep Homeopathic Medical college and research Centre, Vidhyadeep University,  
Anita, Surat

<sup>2</sup>Dr. Gujarathi's Homeopathic Clinic, Kim, Surat

<sup>3</sup>Vidhyadeep Institute of Pharmacy, Vidhyadeep University, Anita, Surat

### Abstract

Eczema is a chronic, recurrent inflammatory skin disorder marked by redness, itching, dryness, scaly patches, oozing, crusting, and occasional blister formation due to reduced barrier function. Conventional treatment, including emollients and corticosteroids, often suppresses symptoms temporarily and relapses commonly occur after discontinuation. Homeopathy offers an alternative approach aimed at treating the underlying imbalance rather than suppressing local manifestations.

This case report describes a 42-year-old male with chronic eczema affecting both thumbs. He was treated with Graphites 0/1 based on individualized totality of symptoms. Significant improvement was observed, including complete recovery of skin symptoms and relief from associated constipation. This case highlights the potential of individualized LM potency homeopathic treatment in managing eczema and supports the need for larger, systematic studies.

**Keywords:** Homeopathy, Eczema, Atopic dermatitis, Graphites, LM potency, Totality of symptoms

## 1. Introduction

Eczema is a chronic, recurrent inflammatory dermatological condition characterized by itching, erythema, dryness, scaling, oozing, crusting, and occasional blistering (Das & Sethi, 2021; Sohn et al., 2011). Although often used interchangeably with dermatitis, eczema is most commonly associated with atopic dermatitis (Kaur et al., 2023; Parveen, 2016). Persistent itching is the hallmark symptom, and the disease significantly affects quality of life, especially in adults. Diagnosis is mainly clinical, based on both subjective and objective indicators (Mandal et al., 2021; Meena et al., 2020).

Management typically includes avoidance of irritants and regular use of emollients. In conventional medicine, topical corticosteroids and immunomodulators are frequently used, but these may suppress symptoms without addressing the underlying cause, leading to relapse after treatment cessation.

Homeopathy views skin disorders as expressions of internal imbalance. According to homeopathic principles, local suppression may drive pathology deeper, potentially causing more serious systemic disturbances over time (Bagdi & Ram, 2020). While several published reports describe the benefits of individualized homeopathic treatment for eczema, well-designed clinical studies remain limited. This case contributes further evidence on the potential role of homeopathy in treating chronic eczema (Kaur et al., 2023; Meena et al., 2020; Mahesh et al., 2021).

This report presents a case of eczema successfully treated with Graphites in LM potency after a detailed assessment of the totality of symptoms.

## 2. Case report

**Patient details** A 42-year-old male visited the clinic on 15 June 2022 with eczematous lesions on the thumbs of both hands. The lesions had been present for 6–7 months. His main symptoms included itching and sticky watery discharge from the lesions. The condition started on the right thumb and later appeared on the left. He also reported constipation for the past six months.

He works as a milk vendor and denied any chemical exposure. He had used allopathic ointments earlier but without satisfactory relief.

**Homeopathic assessment** Based on sticky discharge from skin lesions, chronicity, and associated constipation, Graphites 0/1 was selected after referring to materia medica. The patient was advised to avoid any other treatment and use coconut oil only if dryness occurred.

### 3. Follow-up details

**19 July 2023** the patient reported reduced itching and pain with no discharge. Constipation also improved. Graphites 0/1 was repeated twice daily for 15 days.

**5 August 2023** Skin eruptions significantly decreased; no itching was present. Constipation was completely resolved, with daily soft stools. Graphites 0/1 was advised once daily, and Saccharum Lactis 4 pills three times a day for 15 days.

**23 August 2023** Marked improvement in all symptoms. Only Saccharum Lactis was continued.

**Up to 15 January 2024** The patient was followed regularly and was maintained on placebo. Skin remained clear and healthy with no recurrence. Constipation stayed resolved. The patient also reported feeling mentally calmer with improved decision-making.

**Prescription summary:** 04/07/2023 – Graphites 0/1 BD for 15 days

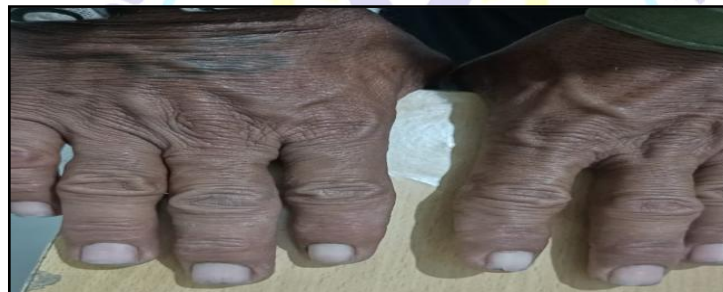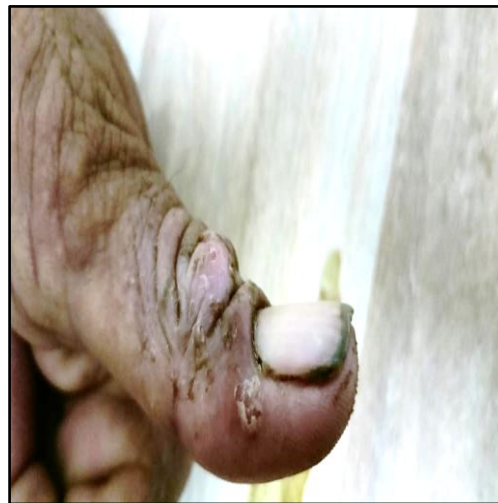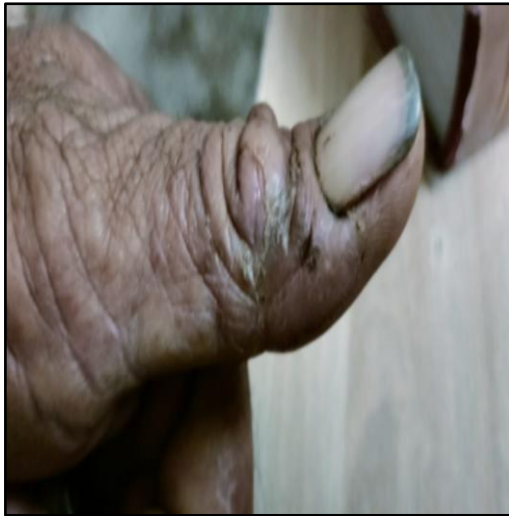### 4. Discussion and conclusion

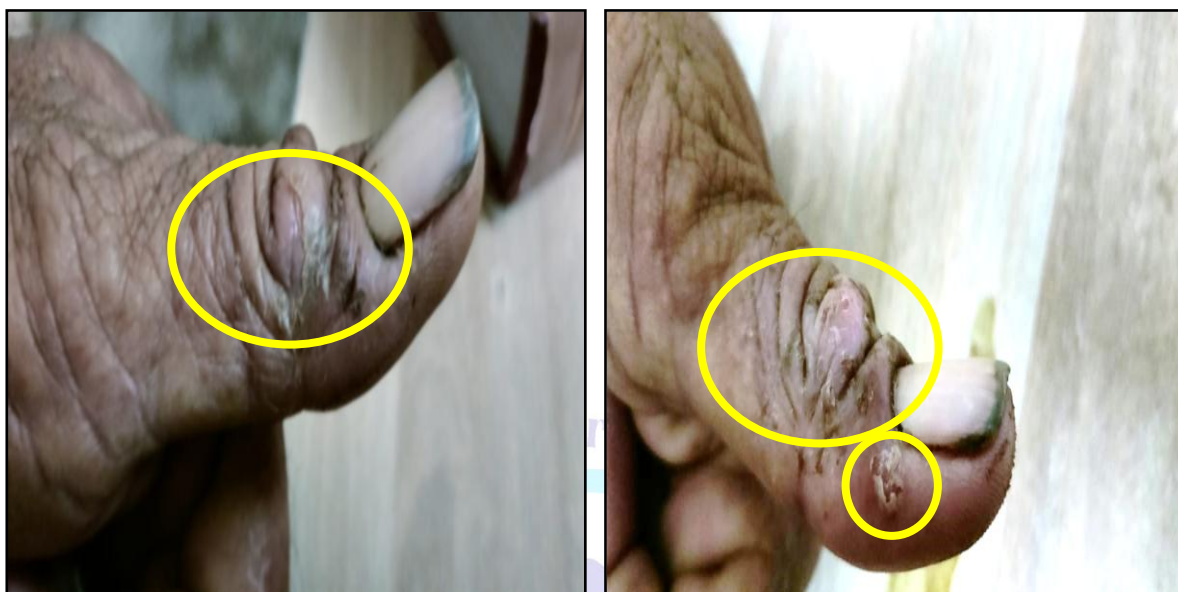
Several published cases and observational studies indicate that individualized homeopathic treatment may help manage chronic skin conditions effectively. According to homeopathic philosophy, external manifestations are the result of internal derangement and should be treated constitutionally rather than suppressed locally.

In this case, Graphites 0/1 was chosen based on the totality of symptoms, including sticky skin discharge and chronic constipation. Notable improvement was seen within 15 days, with cessation of discharge, reduction in itching, and relief of constipation. Complete disappearance of eruptions was observed within one month. Sustained improvement was maintained with placebo, and no recurrence was recorded over several months of follow-up.

This case shows that individualized LM potency homeopathic treatment may offer sustained relief in eczema. However, as this is a single case, larger and well-designed studies are needed to validate effectiveness and generalizability.

**Prescription – date – 4/7/2023 – Graphites 0/1 BD for 15 days**





#### 5. Declaration of patient consent

The author certifies that appropriate patient consent was obtained.

#### 6. Financial support and sponsorship

Nil.

#### 7. Conflict of interest

None declared.

#### 8. References

- Bagdi, N., & Ram, H. (2020). A case report for successful treatment of atopic dermatitis (AD) with a constitutional homoeopathic medicine Natrum muriaticum. *International Journal of Homoeopathic Sciences*, 4(2), 46–51.
- Das, A., & Sethi, S. (2021). *Concise Dermatology* (R. Sarkar, Ed.). CRC Press.
- Kaur, H., Parveen, G., Sengupta, S. S., Hashmi, T. (2023). Homoeopathic management of eczema: A case report. <https://doi.org/10.5281/zenodo.10446391>
- Mahesh, S., Mallappa, M., Habchi, O., Konstanta, V., Chise, C., Sykiotou, P., & Vithoukas, G. (2021). Appearance of acute inflammatory state indicates improvement in atopic



dermatitis under classical homeopathic treatment: A case series. *Clinical Medicine Insights: Case Reports*, 14.

Mandal, S., Biswas, B., & Abbas, J. (2021). Atopic dermatitis in a 2-year-old child treated with individualized homoeopathic medicine: A case report. *Journal of Integrated Standardized Homoeopathy*, 4, 86–93.

Meena, B. S., Kumar, A., & Bagdi, N. (2020). A case of eczema treated with homoeopathic medicine. *Journal of Integrated Standardized Homoeopathy*, 3, 20–23.

Parveen, S. (2016). Homoeopathic treatment in a case of co-morbid atopic dermatitis and depressive disorder. *Indian Journal of Research in Homoeopathy*, 10(1), 75.

Sohn, A., Frankel, A., Patel, R. V., & Goldenberg, G. (2011). Eczema. *Mount Sinai Journal of Medicine*, 78(5), 730–739.

